

Treatment of Multi-level Discogenic Low Back Pain with Bone Marrow Concentrate

Kenneth A. Pettine^{1*} and Tyler J. Santomaso

¹Elite Regenerative stem cell Specialists, 4795 Larimer Parkway, Johnstown Colorado 80534, USA

Received March 7, 2017; Accepted March 22, 2017; Published July 27, 2017

ABSTRACT

Background: Fusion and disc replacement surgeries are common surgical procedures to treat discogenic low back pain affecting one or two lumbar levels, however there remains millions of patients with significant degenerative pathologies at 3 or more levels. Surgery to repair 3 or more degenerated levels is typically unsuccessful and virtually always avoided by surgeons and insurance companies alike

Purpose/Hypothesis: Many animal studies, and limited human trials have demonstrated the safety and efficacy of mesenchymal stem cell (MSC) based treatments for discogenic low back pain. Providing a biologic intervention for patients with 3 or more degenerated discs rather than typical palliative (pain control, physical therapy) measures could change the way discogenic back pain is treated.

Study Design: Prospective, non-randomized, open label

Methods: Patients included male and female participants ranging in age from 17-80 years old (average 53), and BMI ranging from 18.6 to 46.6 Kg/m² (average 27). One hundred forty six patients were studied based on having MRI documented disc degeneration at three or more lumbar levels (modified Pfirrmann grade of 5-7) and at least 6 months of attempted conservative care. MSCs were harvested in the form of bone marrow aspirate from the iliac crest to obtain bone marrow concentrate (BMC). The average patient had 3.6 levels treated. Outcomes were measured by Oswestry Disability Index scores (ODI) and Visual Analog Scale pain scores (VAS) pre-treatment, and at 3, 6, and 12 months. Adverse events were monitored throughout the study.

Results: There were no serious adverse events reported. Patient average pre treatment scores (ODI / VAS) were 41.81 / 63.29, for 3 month patients 14.52/21.06, for 6 month patients 16.04/22.16 and 14.08/19.65 at 12 months. At 3 months the average patient improved by 65.3% / 66.7% respectively, at 6 months by 59.8% / 63.8%, and at 12 months improved by 64.7% / 69% (all values $p < 0.001$). There were no serious adverse events reported, and no patient had increased pain or disability following the injections.. Two patients went on to have surgery during the study, both for indications other than discogenic low back pain (one had a foraminotomy, one a fusion for retrolisthesis from a new injury at a level adjacent to the treatment levels)

Conclusions: These results are superior to reported results of one or two level surgical treatments (average improvement 35 to 40%) and conservative measures (20 to 25%) for the same diagnosis. The BMC injection patients had a higher percentage improvement and there were fewer complications (revisions, infections etc.). Patient improvement was maintained from 3 months through the twelve month follow up (from 3 to 12 months $p = 0.76$). Utilizing MSCs derived from BMC, based on these preliminary results, may offer patients with multi-level discogenic back pain a viable treatment option.

INTRODUCTION

Back pain is the second most common reason for physician visits in the United States and the most common cause of missed work [1-3]. Costs for back pain treatment in the U.S. are estimated to be at \$100 billion annually [4].

Corresponding author: Kenneth A. Pettine, Elite Regenerative stem cell Specialists, 4795 Larimer Parkway, Johnstown Colorado 80534, USA.

Citation: Pettine K A & Santomaso T J. (2017) Treatment of Multi-level Discogenic Low Back Pain with Bone Marrow Concentrate. Stem Cell Res Th, 2(1): 74-79.

Copyright: ©2017 Pettine K A & Santomaso T J. This is an open-access article distributed under the terms of the Creative Commons Attribution License, which permits unrestricted use, distribution, and reproduction in any medium, provided the original author and source are credited.

Current non-operative treatments for chronic discogenic back pain include activity modification, chiropractic care, exercise, physical therapy, medications, and multiple steroid injections [2,5]. Surgical treatments for severe chronic back pain are fusion or artificial disc replacement. The clinical results of one- or two-level lumbar fusion for discogenic back pain are less than optimal compared to other orthopedic procedures [6]. The consensus among spine surgeons is patients with more than two segments of discogenic back pain have no surgical options and a poor prognosis [6,7]. Millions of patients have MRI scans which document abnormalities in three or more lumbar discs [2]. These patients are typically referred to chronic pain management clinics where many end up on high-dose narcotic regimens and multiple steroid injections [1-5,7,8]. Many of these patients are also unemployable [9]. The economic and emotional impact of chronic low back pain on both society and the individual patient is significant. Similar to other chronic conditions, the treatment of multi-level discogenic back pain can cost millions of dollars over a lifetime [2-4,7].

The lumbar disc is the largest avascular structure in your body. As a result, cartilage cells in the nucleus and annulus of the intervertebral disc have little capacity to heal annular tears or correct the degenerative process of dehydration [10]. There is increasing literature to support the efficacy of injecting discs with mesenchymal stem cells (MSCs) in an attempt to reverse or slow down the degenerative process [11-20]. One previous study [21] has demonstrated this procedure has the capacity to restore hydration to the disc based on MRI evidence of modified Pfirrmann grade improvement in human subjects. The purpose of this study is to determine if MSCs in bone marrow concentrate (BMC) have safety and efficacy to treat patients with three or more levels of discogenic low back pain.

MATERIALS AND METHODS

This study is a prospective open-label non-randomized evaluation of 146 patients having an injection of BMC into three or more lumbar discs. Patients were enrolled as subjects in the study if they presented with symptomatic moderate to severe discogenic low back pain as defined by the following criteria: centralized chronic low back pain increased by activity and lasting at least six months; history of non-operative management for six months without resolution; change in normal disc morphology as defined by MRI evaluation with a modified Pfirrmann score of 5 to 7; modic grade-2 change or less; disc height loss of less than 90% compared to an adjacent non-pathologic disc; pre-treatment baseline Oswestry disability index (ODI) of at least 30/100 and pre-treatment baseline low back pain of at least 40mm/100mm visual analog scale (VAS). An intact annulus was not required to be in the study. All patients underwent a pre-injection medical history and physical including an ODI and VAS. These tests were repeated at three-, six-, and 12-months post-injection of BMC. All patients had a normal

neurologic examination of the lower extremities, demonstrated loss of lumbar range of motion, and had pain to deep palpation over the symptomatic discs with associated muscle spasms. Standard exclusion criteria included: an abnormal neurologic examination; symptomatic compressive pathology due to stenosis or herniation; or any spondylolisthesis or spondylolysis. Study patient demographics are listed in **Table 1**.

Table 1. Patient demographics

Number of Patients (n)	Avg. Age : Range	Avg. BMI : Range	M/F
146	52.7 : 17 - 80 yrs. old	27.02 : 18.6 - 46.6 Kg/m ²	79 male/67 female

The most common procedure based on discs injected were the 3 lower lumbar discs (L3 to S1), and the least likely disc to be injected were those in the lower thoracic and at the thoracolumbar junction (T12-L1 and L1-2).

Bone marrow collection and processing

Bone marrow aspirate (BMA, 55ml) was collected over Acid Citrate Dextrose-anticoagulant (ACD-A, 5ml) from the patient's posterior iliac crest. The procedure was performed with IV sedation consisting of Versed and Fentanyl. Positioning of the Jamshidi needle in the iliac wing was confirmed by fluoroscopy. BMA was collected in a 60ml syringe in a series of discrete pulls on the plunger (targeting a collection of 5-10ml/pull), with repositioning of the needle tip between pulls based on the reported enrichment of progenitor cells by Hernigou et al. [22]. The BMA was processed using the ART bone marrow concentration system (Selling Biosciences, Austin, Texas) to produce a bone marrow concentrated cell preparation. The 55 mL of BMA was centrifuged for 12 minutes to produce up to 10 mL of BMC. The BMC was drawn from the processing device, the glucose and bicarbonate were added to the BMC. The BMC with the additives was immediately transferred to the physician for injection [23]. Typically, a BMC volume was drawn from the process device to allow 2ml to be injected into each degenerated disc up to a maximum of 10ml of BMC.

Intradiscal injection

With the patient in a prone position, the injection sites were treated with local anesthetic (1% buffered Lidocaine). BMC was percutaneously injected into the symptomatic discs through a standard posterolateral discogram approach with a two-needle technique. An 18 gauge needle was placed against the posterior right corner of the annulus with the position verified utilizing fluoroscopy. A 22 gauge needle was then placed into the center of the nucleus. The injection point of the 22-gauge needle was verified by fluoroscopy. Approximately 2-3ml of BMC were used per symptomatic lumbar disc injection. The entire procedure averaged less

than 45 minutes. Patients were prescribed pain medication to use as needed for three days and put on restricted physical activity for two weeks.

Clinical Outcomes Determination and Statistical Analysis: ODI and VAS scores were collected from patients by non-investigator personnel employed by the clinic. Univariable data comparisons were analyzed by two-tailed Student t-test with a 95% confidence interval ($\alpha=0.05$, Microsoft Excel). Multivariable data were determined with analysis of variance (ANOVA) using JMP 9 statistical analysis software (SAS Institute, Cary, NC).

Results

There were no complications from harvesting of the BMC or the disc injections. Not every patient improved statistically, but no patient reported increases in VAS or ODI from pre-treatment scores. There were four patients eliminated from the data: one was in an ATV accident, one developed a cyst in a non-treated vertebra unrelated to the injection, and two patients decided to proceed with surgical treatment for indications other than discogenic back pain.

Table 2. Distribution of injected discs

Average number of discs injected per patient: 3.6

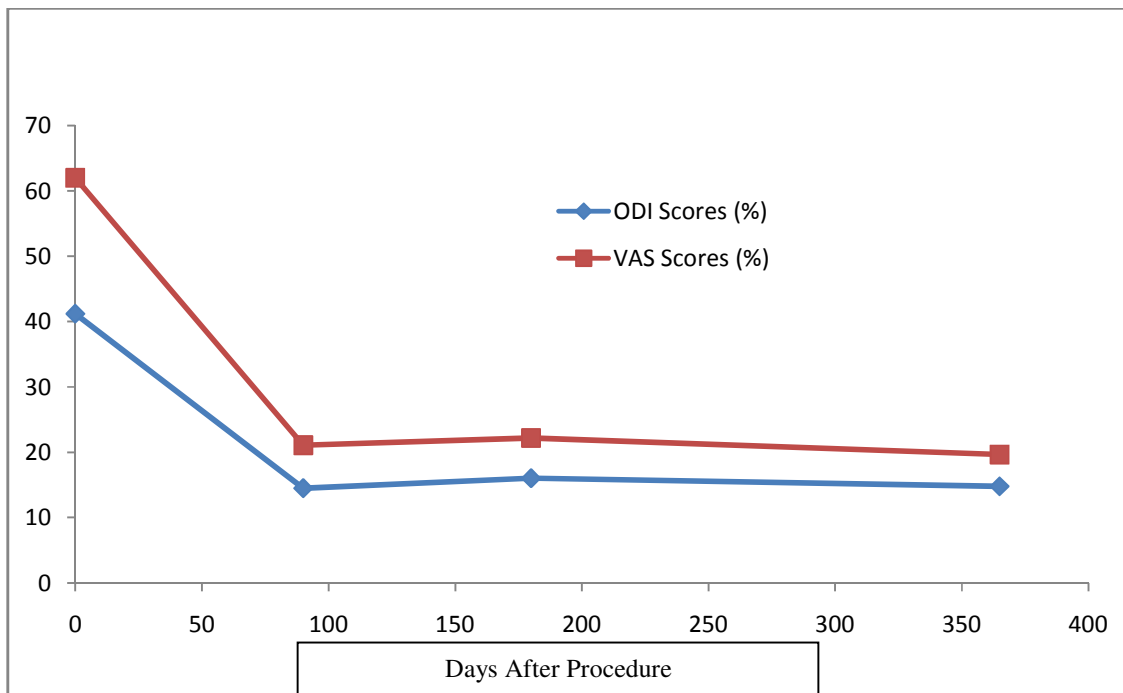
Level	T12-L1	L1-2	L2-3	L3-4	L4-5	L5-S1
Frequency	5	29	83	135	141	115

Table 3. Change in patient reported outcome scores, Oswestry Disability Index (0 – 100) and Visual Analog Scale pain score (0 – 100)

Days after procedure	ODI and VAS averages, % improved from baseline
0	ODI = 41.13, VAS = 62.58 (BASELINE)
90	ODI = 14.52*, VAS = 21.06* (65.3% and 66.7% improved)
180	ODI = 16.04*, VAS = 22.16* (59.8% and 63.8% improved)
365	ODI = 14.80*, VAS = 19.65* (64.7% and 69% improved)

*p-values < 0.001

Figure 1. PREPROCEDURE ODI/VAS scores vs. Post Procedure ODI/VAS scores



*p-values < 0.001

All the patients who had their injections greater than 12 months prior to the writing of this paper were called for final follow-up, and were also asked about the amount of epidural steroid injections (ESIs) and daily narcotics/NSAIDs they were taking before and after the stem cell injection. No patient who responded reported having any ESIs after having his/her disc injected with BMC. The average patient had decreased narcotic/NSAID intake by ~50% following the BMC injection, and no patient reported increased consumption of narcotic/NSAID pain medication.

DISCUSSION

Millions of patients have multiple levels of abnormal discs based on MRI scanning [1]. Almost all causes of multi-level discogenic low back pain patients are of unknown etiology. These patients develop progressive degeneration of multiple discs likely due to a genetic component [9,10,24,25]. Desiccated discs on MRI scanning can be seen in patients as young as 16 [10,21]. Most every surgeon would agree performing a three-, four-, or five-level fusion for discogenic back pain is not a reasonable surgical option. Phillips et al. [6] published an excellent systematic review on the treatment of chronic discogenic low back pain. After establishing strict quality and level of evidence requirements for the review trials, they reported on 26 studies. All patients had one or two abnormal discs with results of the review showing a weighted average of 35.3% improvement in the surgical group (547 patients) and a 20% improvement in the non-surgical group (372 patients). Twelve prospective randomized studies were reviewed comparing various fusion techniques with a minimum two-year follow-up. These patients again were restricted to one or two levels. The results were 43.3% improvement in back pain (1,420 patients) with a re-operation rate of 15.3%. These results along with other meta-analysis of fusion surgeries versus non-operative care demonstrate that even within the context of one or two degenerated discs, fusion surgery provides less than optimal outcomes, and in an appreciable amount of cases, actually makes things worse [26,27]. The minimal data available on three or more level fusions in the context of degenerative disc disease is inconsistent and typically shows poor outcomes. This is the prime reason most surgeons will not attempt the procedure. The lack of clinical data showing surgical efficacy makes insurance coverage for multi-level fusion for discogenic back pain very difficult [9,24].

Mesenchymal stem cells (MSCs) have many positive attributes and have mounting evidence of safety in human use [28-30]. BMC is a source of MSCs. MSCs are anti-inflammatory, secrete numerous growth factors, stimulate blood vessel formation, modulate your immune system to enhance healing, fight bacteria, and turn into cartilage cells to potentially heal damaged discs in the lumbar area [11-20,28,31,32]. Circumventing the circulation limitations of articular structures like the intervertebral disc by local

injection of BMC is hypothesized to expose these areas to the body's potential regenerative healing mechanisms where MSCs would normally be occluded. MSC's through paracrine cellular communication modulate the regenerative environment via anti-inflammatory and immunomodulatory mechanisms. In response to inflammatory molecules such as interleukin-1 (IL-1), IL-2, IL-12, tumor necrosis factor-alpha, and interferon-gamma, MSC's secrete an array of growth factors and anti-inflammatory proteins to modulate many types of immune cells. These paracrine mechanisms may explain some of the MSC's efficacy in treating disc pathology [28].

There is research published primarily in animals documenting the safety and efficacy of MSCs to treat damaged discs and many other orthopedic conditions. MSC based treatments have become standard of practice in veterinary medicine [11-20,33-40]. We have published our one-year and two-year minimum follow-up results from treating patients with BMC having only one or two degenerated discs with symptomatic low back pain. These studies show treating patients with one or two levels of discogenic low back pain results in improvement of VAS and ODI similar to the current study on treating patients with three or more levels [21,41].

Limitations of this study include: no randomized control, no follow up MRI scan data and no cell count data. The author has published MRI follow up data and cell count data in a similar group of patients with the same pathology. [21,41].

CONCLUSION

Patients with more than two levels of symptomatic discogenic low back pain have limited treatment options. There is minimal literature reporting the long-term efficacy of any non-operative treatment (chronic narcotics and multiple steroid injections), and these patients basically have no surgical options. One-year follow-up in treating multi-level discogenic low back pain with BMC showed an average 65% improvement in ODI (p-value<0.001) and 70% improvement in VAS (p-value<0.001) No patient was made worse from the procedure, and there were no complications from the percutaneous injection of BMC into the discs. Utilizing MSCs derived from bone marrow concentrate, based on these preliminary results, may offer patients with multi-level discogenic low-back pain a viable treatment option.

REFERENCES

1. Andersson GB (1999) Epidemiological features of chronic low-back pain. *Lancet* 354: 581-585.
2. Freburger JK, Holmes GM, Agans RP, Jackman AM, Darter JD, et al. (2009) The rising prevalence of chronic low back pain. *Arch Intern Med* 169: 251-258.

3. Deyo RA, Weinstein JN (2001) Low back pain. *N Engl J Med* 344: 363-370.
4. Katz JN (2006) Lumbar disc disorders and low-back pain: socioeconomic factors and consequences. *J Bone Joint Surg Am* 88: 21-24.
5. Dagenais S, Caro J, Haldeman S (2008) A systematic review of low back pain cost of illness studies in the United States and internationally. *Spine J* 8: 8-20.
6. Phillips FM, Slosar PJ, Youssef JA, et al. (2013) Lumbar spine fusion for chronic low back pain due to degenerative disc disease. *Spine* 38: E409-22.
7. van Tulder MW, Koes BW, Bouter LM (1995) A cost-of-illness study of back pain in The Netherlands. *Pain* 62: 233-240.
8. White AP, Arnold PM, Norvell DC, Ecker E, Fehlings MG (2011) Pharmacologic management of chronic low back pain: synthesis of the evidence. *Spine (Phila Pa 1976)* 36: S131-143.
9. Chou R, Carragee JB, Eugene J, Resnick DK, Shaffer WO, et al. (2009) Surgery for Low Back Pain: A Review of the Evidence for an American Pain Society Clinical Practice Guideline *Spine (Phila PA 1976)* 34: 1094-1109.
10. Vergroesen P, Kingma I, manuel KS, Hoogendoorn RJ, Welting TJ, et al. (2015) Mechanics and biology in inintervertebral disc degeneration: A vicious circle. *Osteoarthritis and Cartilage*.
11. Sakai D, Andersson GB (2015) Stem cell therapy for intervertebral disc regeneration: obstacles and solutions. *Nat Rev Rheumatol* 11: 243-256.
12. Yim R, Lee J, Bow C, Meij B, Leung V, et al. (2014) A systematic review of the safety and efficacy of mesenchymal stem cells for disc degeneration: Insights and future directions for regenerative therapeutics. *Stem Cells Dev* 23: 2553-2567.
13. Acosta F, Metz L, Adkisson H, Liu J, Liebenberg EC, et al. (2011) Porcine intervertebral disc repair using allogeneic juvenile articular chondrocytes or mesenchymal stem cells. *Tissue Eng Part A* 17: 3045-3055.
14. Allon AA, Aurouer N, Yoo BB, Liebenberg EC, Buser Z, et al. (2010) Structured coculture of stem cells and disc cells prevent disc degeneration in a rat model. *Spine J* 10: 1089-1097.
15. Bendtsen M, Bungler C, Zhou X, Foldager C, Jorgensen HS (2011) Autologous stem cell therapy maintains vertebral blood flow and contrast diffusion through the endplate in experimental intervertebral disc degeneration. *Spine (Phila PA 1976)* 36: E373-E379.
16. Feng G, Zhao X, Liu H, Zhang H, Chen X, et al. (2011) Transplantation of mesenchymal stem cells and nucleus pulposus cells in a degenerative disc model in rabbits: a comparison of 2 cell types as potential candidates for disc regeneration. *J Neurosurgery Spine* 14: 322-329.
17. Ghosh P, Moore R, Vernon-Roberts B, Goldschlager T, Pascoe D, et al. (2012) Immunoselected STRO-3+ mesenchymal precursor cells and restoration of the extracellular matrix of degenerate intervertebral discs. *J Neurosurgery Spine* 16: 479-488.
18. Hee HT, Ismail HD, Lim CT, Goh JC, Wong HK (2010) Effects of implantation of bone marrow mesenchymal stem cells, disc distraction and combined therapy on reversing degeneration of the intervertebral disc. *J Bone Joint Surg Br* 92: 726-736.
19. Hiyama A, Mochida J, Iwashina T, Omi H, Watanabe T, et al. (2008) Transplantation of mesenchymal stem cells in a canine disc degeneration model. *J Orthop Res* 26: 589-600.
20. Sakai D, Mochida J, Iwashina T, Watanabe T, Nakai T, et al. (2005) Differentiation of mesenchymal stem cells transplanted to a rabbit degenerative disc model: potential and limitations for stem cell therapy in disc degeneration. *Spine (Phila PA 1976)* 30: 2379-2387.
21. Pettine K, Murphy M, Suzuki R, Sand T (2015) Percutaneous injection of autologous bone marrow concentrate cells significantly reduces lumbar discogenic pain through 12 months. *Stem Cells* 33: 146-156.
22. Hernigou P, Mathieu G, Poignard A, Manicom O, Beaujean F, et al. (2006) Percutaneous autologous bone-marrow grafting for nonunions. *Surgical technique. J Bone Joint Surg Am* 88: 322-327.
23. Pettine K (2013) Regenerative Autologous Bone Marrow Cell Therapies and Methods for their use in the treatment of joint pain.
24. Röllinghoff M, Schlüter-Brust K, Groos D, Sobottke R, Michael JW, et al. (2010) Mid-range outcomes in 64 consecutive cases of multilevel fusion for degenerative diseases of the lumbar spine. *Orthop Rev (Pavia)* 2: e3.
25. Vora RN, Barron BA, Almudevar A, Utell MJ (2012) Work-related chronic low back pain-return-to-work outcomes after referral to interventional

- pain and spine clinics. *Spine (Phila Pa 1976)* 37: E1282-1289.
26. Bydon M, De la Garza-Ramos R, Macki M, Baker A, Gokaslan AK, et al. (2014) Lumbar fusion vs. non-operative management for treatment of discogenic low back pain: a systematic review and meta-analysis of randomized controlled trials. *J Spinal Discord Tech.*
 27. Saltychev M, Eskola M, Laimi K (2014) Lumbar fusion compared with conservative treatment in patients with chronic low back pain: a meta-analysis. *Int J Rehabil Res* 37: 2-8.
 28. Murphy MB, Moncivais K, Caplan AI (2013) Mesenchymal Stem Cells: environmentally responsive therapeutics for regenerative medicine. *Exp Mol Med.*
 29. Lalu MM, McIntyre L, Pugliese C, Fergusson D, Winston BW, et al. (2012) Safety of cell therapy with mesenchymal stromal cells (SafeCell): a systematic review and meta-analysis of clinical trials. *PLoS One* 7: e47559.
 30. Peeters CM, Leijts MJ, Reijman M, van Osch GJ, Bos PK (2013) Safety of intra-articular cell-therapy with culture-expanded stem cells in humans: a systematic literature review. *Osteoarthritis Cartilage* 21: 1465-1473.
 31. Counsel PD, Bates D, Boyd R, Connell DA (2015) Cell therapy in joint disorders. *Sports Health* 7: 27-37.
 32. Kristjánsson B, Honsawek S (2014) Current perspectives in mesenchymal stem cell therapies for osteoarthritis. *Stem Cells Int* 2014: 194318.
 33. Black LL, Gaynor J, Adams C, Dhupa S, Sams AE, et al. (2008) Effect of intraarticular injection of autologous adipose-derived mesenchymal stem and regenerative cells on clinical signs of chronic osteoarthritis of the elbow joint in dogs. *Vet Ther* 9: 192-200.
 34. Chang CH, Kuo TF, Lin FH, Wang JH, Hsu YM, et al. (2011) Tissue engineering-based cartilage repair with mesenchymal stem cells in a porcine model. *J Orthop Res* 29: 1874-1880.
 35. Guercio A, Di Marco P, Casella S, Cannella V, Russotto L, et al. (2012) Production of canine mesenchymal stem cells from adipose tissue and their application in dogs with chronic osteoarthritis of the humeroradial joints. *Cell Biol Int* 36: 189-194.
 36. Lee KB, Hui JH, Song IC, Ardany L, Lee EH (2007) Injectable mesenchymal stem cell therapy for large cartilage defects--a porcine model. *Stem Cells* 25: 2964-2971.
 37. Sato M, Uchida K, Nakajima H, Miyazaki T, Guerrero AR, et al. (2012) Direct transplantation of mesenchymal stem cells into the knee joints of Hartley strain guinea pigs with spontaneous osteoarthritis. *Arthritis Res Ther* 14: R31.
 38. Murphy JM, Fink DJ, Hunziker EB, Barry FP (2003) Stem cell therapy in a caprine model of osteoarthritis. *Arthritis Rheum* 48: 3464-3474.
 39. Mokbel A, El-Tookhy O, Shamaa AA, Sabry D, Rashed L, et al. (2011) Homing and efficacy of intra-articular injection of autologous mesenchymal stem cells in experimental chondral defects in dogs. *Clin Exp Rheumatol* 29: 275-84.
 40. Mokbel AN, El Tookhy OS, Shamaa AA, Rashed LA, Sabry D, et al. (2011) Homing and reparative effect of intra-articular injection of autologous mesenchymal stem cells in osteoarthritis animal model. *BMC Musculoskelet Disord* 12: 259.
 41. Pettine K, Suzuki R, Sand T, Murphy M (2016) Treatment of discogenic back pain with autologous bone marrow concentrate injection with minimum two year follow-up. *Int Orthop* 40: 135-140.